

Low-Intensity Extracorporeal Shockwave Therapy (LI-ESWT) in Renal Diseases: A Review of Animal and Human Studies

Sune Moeller Skov-Jepesen^{1,2}, Nicky Anúel Petersen¹, Knud Bonnet Yderstraede^{2,3}, Boye L Jensen⁴, Claus Bistrup^{2,5}, Lars Lund^{1,2}

¹Department of Urology, Odense University Hospital, Odense, Denmark; ²Clinical Institute, University of Southern Denmark, Odense, Denmark;

³Department of Endocrinology, Odense University Hospital, Odense, Denmark; ⁴Department of Cardiovascular and Renal Research, Institute of Molecular Medicine, University of Southern Denmark, Odense, Denmark; ⁵Department of Nephrology, Odense University Hospital, Odense, Denmark

Correspondence: Sune Moeller Skov-Jepesen, Department of Urology, Odense University Hospital, Sdr. Boulevard 29, Odense, 5000, Denmark, Tel +45 51210911, Fax +45 65411726, Email sun_mjep@hotmail.com

Background: Low-intensity extracorporeal shockwave therapy (LI-ESWT) has been suggested as a treatment for vascular diseases such as ischemic heart disease, diabetic foot ulcers, and erectile dysfunction. Primarily, LI-ESWT is known for its ability to stimulate angiogenesis and activation of stem cells in target tissues. Application of LI-ESWT in chronic progressive renal diseases is a novel area. The aim of the present review was to summarize available data on the effects of LI-ESWT used in the setting of renal diseases.

Methods: We systematically searched PubMed, Medline, and Embase databases for relevant studies. Our review included the results from preclinical animal experiments and clinical research.

Results: Eleven animal studies and one clinical study were included in the review. In the animal studies, LI-ESWT was used for the treatment of hypertensive nephropathy (n=1), diabetic nephropathy (n=1), or various types of ischemic renal injury (ie, artery occlusion, reperfusion injury) (n=9). The clinical study was conducted in a single-arm cohort as a Phase 1 study with patients having diabetic nephropathy. In animal studies, the application of LI-ESWT was associated with several effects: LI-ESWT led to increased VEGF and endothelial cell proliferation and improved vascularity and perfusion of the kidney tissue. LI-ESWT reduced renal inflammation and fibrosis. LI-ESWT caused only mild side effects in the clinical study, and, similarly, there were no signs of kidney injury after LI-ESWT in the animal studies.

Conclusion: LI-ESWT, as a non-invasive treatment, reduces the pathological manifestations (inflammation, capillary rarefaction, fibrosis, decreased perfusion) associated with certain types of renal disease. The efficacy of renal LI-ESWT needs to be confirmed in randomized clinical trials.

Keywords: review, kidney disease, extracorporeal shockwave therapy, ESWT

Background

Low-intensity extracorporeal shockwave therapy (LI-ESWT) is a novel treatment method suggested to stimulate angiogenesis and tissue regeneration in target organs. LI-ESWT is defined as shockwave therapy applied with energy flux density up to 0.35 mJ/mm², which is significantly lower than shockwave lithotripsy (ESWL, typically at energy >0.75 mJ/mm²). In coronary heart disease and peripheral artery disease, LI-ESWT has been applied to increase perfusion and reduce ischemic symptoms.^{1,2} Additionally, LI-ESWT promotes healing of chronic diabetic foot ulcers³ and may be an effective treatment for patients with vasculogenic type of erectile dysfunction.⁴

Shockwaves constitute a type of acoustic waves characterized by a high, short-lasting peak pressure followed by a mild, tensile phase. In biological tissues, the shockwaves induce shear stress upon cell membranes, cytoskeleton, and extracellular matrix. The effect is mediated through the process of mechanotransduction meaning that the physical pressure stimulus is converted into a biological response via sensory molecules on the cell surface.⁵ In the molecular

scale, vascular endothelial growth factor (VEGF) and nitric oxide (NO) are released from endothelial cells in response to LI-ESWT which in turn increases endothelial cell growth, vascular relaxation, and angiogenesis.⁶⁻⁸

Chronic kidney disease (CKD) is characterized by irreversible pathological lesions of the kidney tissue including vascular rarefaction, interstitial fibrosis, and tubular atrophy. In particular, diabetic nephropathy and hypertensive nephropathy are major culprits leading to end-stage kidney disease that is associated with microvascular degeneration and glomerulosclerosis. Other causes that might promote CKD include acute transient renal ischemia, toxic insults/effects, and autoimmune disorders. LI-ESWT could prove as a feasible method to ameliorate the chronic manifestations of renal diseases and preserve kidney function.

The aim of the present systematic review was to assemble current data on LI-ESWT as a potential treatment option for renal diseases. Accordingly, our objective was to systematically collect and summarize existing literature on LI-ESWT treatment for renal diseases. We included both animal and human research data. We excluded studies where shockwave therapy was used in the setting of urological stone disease and cell culture/ex vivo studies.

Methods

We performed a systematic database search for studies on LI-ESWT in combination with renal disease. Both human and animal studies were included. We searched PubMed, Medline, and Embase databases. The following search string was used in PubMed: (shockwave or shockwaves or shock waves or shock wave or ESWT or SWT) and (kidney or kidneys or renal). We used the same terms for search build in the other databases. The databases were searched on August 29, 2022. No restrictions on publication year or language were applied. The search yielded a total of 14,894 articles which was reduced to 7043 different articles after removal of duplicates. Duplicates were identified in EndNote based on similarity between author, title, and year of publication. Finally, the 7043 articles were screened for eligibility by two researchers (S.M.S.J and N.A.P) based on title, abstract, and full-text reading (Flowchart, Figure 1). The two researchers worked

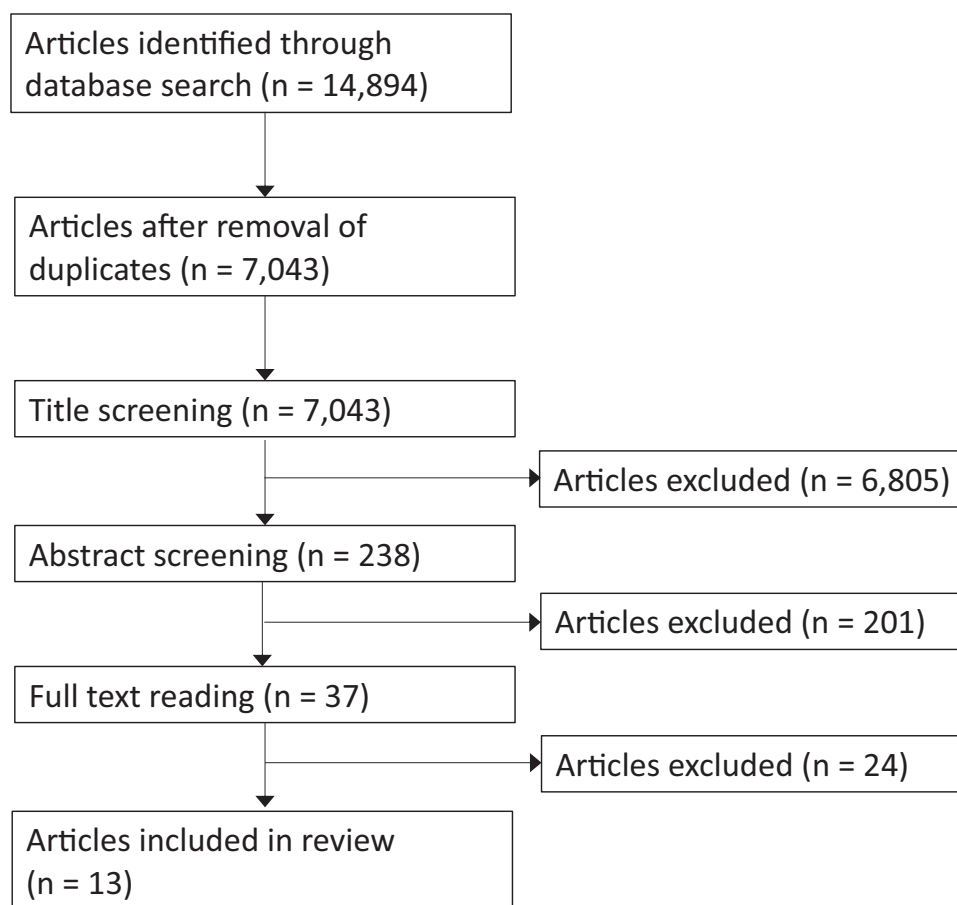


Figure 1 Flowchart.

Box 1 Eligibility Criteria

Inclusion Criteria

- LI-ESWT used as intervention for renal disease
- Human and animal experimental studies

Exclusion criteria

- Lithotripsy/stone disease
- Malignant renal disease
- Shockwave therapy used for ramping or preconditioning in conjunction with lithotripsy
- Study on adverse effects in relation to shock wave lithotripsy
- Non-experimental study (eg, review, editorial, comment, letter).

independently screening the articles before meeting to decide which studies to include in the review. A third researcher (L.L.) would take the decision on study eligibility in case of disagreement between the first two researchers. Furthermore, the literature lists of the eligible studies were screened for additional studies. Inclusion and exclusion criteria for the studies selected for this review are listed in [Box 1](#). LI-ESWT was defined as shockwave therapy carried out with focal zone energy flux below 0.35 mJ/mm^2 (low to medium energy level) in accordance with the guidelines provided by the International Society for Medical Shockwave Treatment (ISMST).⁹ Risk of bias was not assessed for the included studies since no randomized clinical studies were identified.

We screened the WHO International Clinical Trials Registry Platform, ClinicalTrials.gov, the EU Clinical Trials Register, and the Australian New Zealand Clinical Trials Registry for further studies. The registries were searched using the same terms as in our database search.

Results

We identified a total of 12 eligible studies. Of these, 11 were animal studies^{10–20} and one was a clinical study.^{21,22}

We found two preclinical animal studies^{23,24} and two clinical studies^{25,26} that were non-eligible since they were only published in abstract format. Three unpublished clinical studies were located at ClinicalTrials.gov (Identifier: NCT03914157) and WHO International Clinical Trials Registry Platform (Main ID: JPRN-UMIN000030768 and JPRN-UMIN000030448). One unpublished clinical study was located at ClinicalTrials.gov (Identifier: NCT03445247), but the study had been suspended due to a lack of participants. The methods and results of the studies published in abstract format are not further described in the present review, but an overview is included in an [Additional File](#) (see [Additional Tables 1](#) and [2](#)).

Animal Studies

Six of the animal studies used rats^{10,12,15–17,20} and five studies used pigs.^{11,13,14,18,19} In the animal studies, different types of renal disease were induced by either N^0 -nitro-L-arginine methyl ester (L-NAME) ingestion (hypertension, $n=1$),¹⁰ streptozotocin injection (type 1 diabetes mellitus, $n=1$),¹⁵ or renal artery occlusion/stenosis (hypoxic ischemia, $n=9$).^{11–14,16–20} The number of LI-ESWT treatment sessions varied from one single treatment^{12,20} up to a maximum of 12 treatments.¹⁰ The most common protocol for LI-ESWT treatment was two sessions per week for 3 weeks ($n=5$).^{11,13,14,18,19} LI-ESWT was applied either unilaterally ($n=9$)^{10–14,16,18–20} or bilaterally ($n=2$).^{15,17} In the studies with rats, the dosage of LI-ESWT per session varied from 180 shocks/kidney¹⁶ up to 400 shocks/kidney.¹⁰ In the five porcine studies, the dosage of LI-ESWT was the same: the stenotic kidney was divided into 24–26 small zones and each zone was treated with 200 shocks, ie, 4800–5200 shocks/session.^{11,13,14,18,19} The lowest energy level was 0.09 mJ/mm^2 ^{20,11,13,14,18,19} and the highest energy level that was used was 0.13 mJ/mm^2 .¹⁵ Control groups were used in all of the studies, but only five studies^{10–12,18,20} applied a healthy (negative) control group to be treated with LI-ESWT to study potential side effects to LI-ESWT. Treatment with LI-ESWT was carried out using Storz Duolith SD1 ($n=2$),^{16,17} Medispec Omnispec Vetspec ($n=5$),^{11,13,14,18,19} Wikkon.HK. ESWL-Vm ($n=1$),¹² special Medispec device ($n=1$),¹⁰ High Medical Technologies EvoTron R05,¹⁵ or EMS DolorClast.²⁰

Clinical Studies

Skov-Jeppesen et al^{21,22} published a safety report from a clinical study that included measurement of renal functional outcomes after LI-ESWT in patients with diabetic nephropathy. Other studies have reported data only in abstract format. The study by Skov-Jeppesen et al^{21,22} was a single-arm cohort study with relatively small study population including 28 patients. In this study, LI-ESWT was applied with a Storz Modulith SLX-2 device and both kidneys were treated on upper, middle, and lower zone with 1000 shocks/zone and energy 0.265 mJ/mm².²¹

The design and methods of the animal and clinical studies are summarized in Table 1.

Molecular Effects

The protein expression of VEGF was higher in the kidney tissue after LI-ESWT in the studies by Zhang et al,¹¹ Sung et al,¹⁶ Hsiao et al,¹⁵ and Zhao et al.¹⁸ However, there was no change in VEGF mRNA expression after LI-ESWT in the study by Caron et al.¹⁰ Chen et al¹⁴ found that the protein expression of VEGF was unaffected by LI-ESWT. In the study by Yoshida et al,¹⁷ the expression of VEGF mRNA was upregulated in the contralateral, non-treatment kidney. In relation to nitric oxide synthase (NOS) expression, the studies by Zhang et al 2016,¹¹ Sung et al,¹⁶ and Zhao et al¹⁸ found higher endothelial NOS (eNOS) expression after LI-ESWT. On the other hand, in the studies by Caron et al¹⁰ and Yoshida et al,¹⁷ there was no significant effect on eNOS expression. Xue et al¹² found lower levels of inducible NOS (iNOS) after LI-ESWT. Chen et al¹⁹ found that there was no effect of LI-ESWT monotherapy on the expression of eNOS but combination therapy with mesenchymal stem cells caused an upregulation of eNOS. Skov-Jeppesen et al²² reported that nitric oxide metabolites in urine tended to be higher in patients with diabetic nephropathy after treatment with LI-ESWT, but the results were not statistically significant. Furthermore, there seemed to be a transient decrease in VEGF 1 month after LI-ESWT in the clinical study by Skov-Jeppesen et al but the evidence was not strong ($p=0.056$).²² Other findings included lower levels of inflammatory and apoptotic markers after LI-ESWT^{15,16,19} as well as less oxidative stress.^{12,15,16,19} A few studies also investigated the mechanotransduction signal of LI-ESWT suggesting that the shock wave pressure stimulus was mediated through membrane proteins such as focal adhesion kinase (FAK) and beta 1-integrin.^{11,14} Furthermore, LI-ESWT seemed to downregulate TGF-beta expression in the studies by Zhang et al 2016,¹¹ Sung et al,¹⁶ and Hsiao et al¹⁵ This could indicate that LI-ESWT counteracts the initiation of fibrosis. Stromal cell-derived factor-1 (SDF-1), a chemoattractant for endothelial progenitor cells, was higher after LI-ESWT in the setting of renal ischemia,^{11,18,20} diabetic nephropathy,¹⁵ and proteinuric CKD¹⁶ but not in hypertensive renal disease.¹⁰ In summary, available data do not show consistent changes in VEGF and NO-synthase in kidney tissue subjected to LI-ESWT.

Cellular and Histological Effects

A common finding was lower interstitial fibrosis after LI-ESWT as demonstrated by trichrome staining at 4 weeks,^{11,13,18,19} 7 weeks,¹⁴ and 60 days.¹⁶ Nonetheless, two studies found no effect of LI-ESWT on the degree of renal fibrosis at 4 days¹⁷ and 4 weeks¹⁰ after the treatment. LI-ESWT promoted endothelial cell proliferation^{16,20} and increased renal vascularity.^{11,14} On microCT scan, Zhang et al¹¹ and Chen et al¹⁹ demonstrated that the density of small renal vessels recovered after LI-ESWT. Three studies^{14,18,19} found higher number of peritubular capillaries after LI-ESWT. Other studies reported ameliorated vascular and glomerular lesions after LI-ESWT¹⁵ as well as lymphangiogenesis.¹⁷ In diabetic rats, LI-ESWT promoted regeneration of glomerular podocyte cells.¹⁵ Intriguingly, the homing of circulating endothelial progenitor cells to kidney tissue was enhanced by LI-ESWT.^{16,18,20} Also, LI-ESWT improved inflammation as indicated by lower infiltration of macrophages.^{14,15} However, LI-ESWT did not affect the number of macrophages after ischemia-reperfusion injury in the study by Yoshida et al¹⁷ In summary, available data show stimulatory effects of LI-ESWT on kidney microvessel density and growth.

Renal Functional Effects

The effect of LI-ESWT on GFR was assessed directly in four of the animal studies^{11,14,18,19} and in the human study.²¹ Four studies^{11,14,18,19} demonstrated that single kidney GFR was significantly higher in pigs 4 weeks after LI-ESWT administration as evidenced by multidetector computed tomography (MDCT). In the clinical study,²¹ GFR was measured in patients by means of chrome-EDTA clearance. After six sessions of LI-ESWT, GFR was stable in patients with diabetic nephropathy up to 6 months.^{21,22} In five of the animal studies, LI-ESWT lowered the plasma concentration of creatinine, BUN, or cystatin

Table 1 Design and Methods

Study	Design	Condition	Intervention	Experimental Groups	LI-ESWT Treatment
Caron et al ¹⁰	Animal study (rats)	Hypertensive, proteinuric renal disease induced by L-NAME ingestion	Left kidney treated 3 times per week for 4 weeks using special Medispec device	1) Non-hypertensive 2) Hypertensive 3) Non-hypertensive +LI-ESWT 4) Hypertensive + LI-ESWT	400 shocks per session at energy 0.09 mJ/mm ²
Zhang et al ¹¹	Animal study (pigs)	Ischemic renal disease induced by unilateral renal artery stenosis (RAS)	Stenotic kidney treated 2 times per week for 3 weeks using Medispec Omnispec Vetspec device	1) Normal 2) RAS 3) Normal +LI-ESWT 4) RAS + LI-ESWT	Kidney divided in 24–26 small zones. Each zone treated with 200 shocks per session at energy 0.09 mJ/mm ² and 2 Hz
Xue et al ¹²	Animal study (rats)	Renal ischemic reperfusion injury after unilateral renal artery occlusion for 45 minutes	Kidney was treated 1 time before renal artery occlusion using Wikkon HK.ESWL-Vm device	1) Normal 2) Reperfusion injury 3) Normal +LI-ESWT 4) Reperfusion injury + LI-ESWT	200 shocks at energy 12 kv and 1 Hz
Zhang et al ¹³	Animal study (pigs)	Ischemic renal disease induced by unilateral renal artery stenosis (RAS)	Stenotic kidney treated 2 times per week for 3 weeks using Medispec Omnispec Vetspec device	1) Normal 2) RAS 3) RAS + LI-ESWT	Kidney divided in 24–26 small zones. Each zone treated with 200 shocks per session at energy 0.09 mJ/mm ² and 2 Hz
Chen et al ¹⁴	Animal study (pigs)	Renal reperfusion injury induced by unilateral renal artery stenosis (RAS) followed by PTR A	After stenosis, before reperfusion, stenotic kidney was treated 2 times per week for 3 weeks using Medispec Omnispec Vetspec device	1) Normal 2) RAS 3) RAS +PTR A 4) RAS + PTR A + LI-ESWT	Kidney divided in 24–26 small zones. Each zone treated with 200 shocks per session at energy 0.09 mJ/mm ² and 2 Hz
Hsiao et al ¹⁵	Animal study (rats)	Diabetic renal disease induced by Streptozotocin injection	Both kidneys treated 1 time per week for 6 weeks using High Medical Technologies EvoTron R05 device	1) Normal 2) Diabetic 3) Diabetic + LI-ESWT	200 shocks at each kidney per session at energy 0.13 mJ/mm ² and frequency 200 shocks/minute.
Sung et al ¹⁶	Animal Study (rats)	Proteinuric chronic renal disease induced by unilateral nephrectomy and contralateral ligation of 2/3 renal blood supply	Endothelial progenitor cells (EPC) were administered intravascularly and supported by DPP4-inhibition and LI-ESWT 1 time per week for 3 weeks on remaining kidney using Storz Duolith SD1 device	1) Normal 2) Renal disease 3) Renal disease + EPC 4) Renal disease + LI-SWT 5) Renal disease + EPC + LI-ESWT	180 shocks per session at energy 0.12 mJ/mm ²
Yoshida et al ¹⁷	Animal study (rats)	Renal ischemic reperfusion injury after unilateral renal artery occlusion for 45 minutes	After reperfusion, both kidneys were treated 3 times over 3 days (early phase study) or 9 times over 16 days (late phase study) using Duolith SD1 device	1) Normal 2) Reperfusion injury 3) Reperfusion injury + LI-ESWT	200 shocks at each kidney per session at energy 0.10 mJ/mm ² distributed over two sites per kidney
Zhao et al ¹⁸	Animal study (pigs)	Ischemic renal disease induced by unilateral renal artery stenosis (RAS)	Stenotic kidney treated 2 times per week for 3 weeks using Medispec Omnispec Vetspec device	1) Normal 2) RAS 3) Normal +LI-ESWT 4) RAS + LI-ESWT	The entire kidney was divided in 1 cm ² zones. Each zone was treated with 200 shocks per session at energy 0.09 mJ/mm ² and 2 hz
Chen et al ¹⁹	Animal study (pigs)	Ischemic renal disease induced by unilateral renal artery stenosis (RAS)	Stenotic kidney treated 2 times per week for 3 weeks using Medispec Omnispec Vetspec device followed by administration of mesenchymal stem cells (MSC) delivered through the renal artery	1) Normal 2) RAS 3) RAS + LI-ESWT 4) RAS + LI-ESWT + MSC	Kidney divided in 24–26 small zones. Each zone treated with 200 shocks per session at energy 0.09 mJ/mm ² and 2 Hz
Liu et al ²⁰	Animal study (rats)	Renal ischemic reperfusion injury after unilateral renal artery occlusion for 45 minutes	Pre-treatment with one session LI-ESWT using DolorClast device. Endothelial progenitor cells (EPC) were administered intravascularly to a subset of animals in each group before intervention.	1) Normal 2) Reperfusion injury 3) LI-ESWT 4) Reperfusion injury + LI-ESWT 5) Normal + EPC 6) Reperfusion injury +EPC 7) LI-ESWT +EPC 8) Reperfusion injury + LI-ESWT + EPC	200 shocks applied to the kidney immediately before ischemic reperfusion injury at energy 0.1 mJ/mm ² and 1 Hz.
Skov-Jepsen et al ^{21,22}	Clinical single-arm cohort study with 28 patients	Patients with diabetic renal disease and eGFR 30–60 mL/min/1.73m ²	Both kidneys treated 2 times per week for 3 weeks using Storz Modulith SLX-2 device	1) Diabetes + LI-ESWT	Kidneys divided in upper, middle, and lower part. Each part treated with 1000 shocks per session at energy 0.265 mJ/mm ² and 4 Hz

C^{11,12,16,17,20} but there was no significant effect on these parameters in the studies by Caron et al¹⁰ and Chen et al¹⁴. In the animal studies, LI-ESWT improved tissue oxygenation as demonstrated by blood oxygen-level dependent magnetic resonance imaging (BOLD MRI)^{11,14,19} as well as renal arterial flow.^{16,18,19} Two studies, however, did not demonstrate a significant effect of LI-ESWT on renal arterial blood flow.^{11,14} Importantly, LI-ESWT ameliorated albuminuria and proteinuria in preclinical settings. In rats, proteinuria was lower 60 days after LI-ESWT in proteinuric CKD,¹⁶ and albuminuria was lower than 6 weeks after LI-ESWT in diabetic nephropathy.¹⁵ In pigs with renal ischemia, Zhao et al¹⁸ demonstrated that the urinary protein excretion was lowered at 4 weeks after LI-ESWT. However, the studies by Caron et al¹⁰ and Zhang et al¹¹ did not corroborate this. In human diabetic nephropathy, there were no significant changes in median albuminuria 6 months after LI-ESWT.^{21,22} Other functional changes after LI-ESWT included improved arterial blood pressure^{11,13,15,18} which was, however, not confirmed in an animal model of hypertensive nephropathy¹⁰ and a model of renal ischemia.¹⁹ In the human study, ambulatory blood pressure was unchanged after LI-ESWT.^{21,22} In pigs treated with LI-ESWT, Zhao et al¹⁸ demonstrated that the renal blood flow was significantly higher in response to a systemic dose of acetylcholine which could indicate an improvement of the renal microvascular endothelial function. Nonetheless, LI-ESWT monotherapy did not enhance the vascular response to acetylcholine in pigs in the study by Chen et al¹⁸. In summary, LI-ESWT is neutral or slightly beneficial on GFR and albuminuria, but material is scarce and follow-up time is limited.

Safety

LI-ESWT was applied to a healthy control group in four of the animal studies allowing the study of side effects to the treatment. In rat studies, no histological changes were seen after application of LI-ESWT to healthy animals.^{10,12,20} LI-ESWT did not adversely affect urinary protein excretion, arterial blood pressure, or renal function.^{10,20} Furthermore, plasma levels of NGAL and KIM-1 remained unchanged at 24 hours and 1 week after LI-ESWT.¹² In pigs, a single session of LI-ESWT caused no micro- or macroscopic haematuria and no signs of haemorrhage or tubular injury.¹¹ Furthermore, urinary NGAL and protein levels and renal function were stable.¹¹ There were no differences found between healthy pigs treated with six sessions of LI-ESWT and healthy pigs that received no intervention.^{11,18} In the remaining animal studies,^{13,14,16,17,19} LI-ESWT did not negatively affect any of the measured or observed variables. Xue et al¹² found lower iNOS after LI-ESWT which can be interpreted as reduced oxidative stress/macrophage activation and therefore not a negative finding. In the published study with data from patients with diabetes, there was transient macroscopic haematuria in six out of 28 patients after LI-ESWT.²² Treatment with LI-ESWT caused short-lasting flank tenderness in the majority of the patients, and ultrasound scanning revealed no signs of renal hematoma.^{21,22} There were no correlations between the presence of haematuria and negative functional outcomes in the patients.^{21,22} During the intervention, the patients experienced LI-ESWT as a stinging sensation, but pain was only reported in 1/14 patients.²¹ Importantly, in patients with diabetic nephropathy, LI-ESWT had no negative impact on urinary kidney injury markers (KIM-1, calbindin, clusterin, osteonectin, trefoil factor-3).²²

The results of each study are listed in Table 2. Furthermore, Table 3 shows selected molecular, cellular and functional effects of renal LI-ESWT treatment.

Table 2 Results

Study	Main Findings
Caron et al ¹⁰	<ul style="list-style-type: none"> • No effect of LI-ESWT on urine protein excretion, systolic blood pressure, plasma creatinine and BUN, or renal histological lesions • No increases in the mRNA expression of VEGF, VEGF-R2, eNOS, or HIF-1alpha after LI-ESWT • No side effects to LI-ESWT
Zhang et al ¹¹	<ul style="list-style-type: none"> • LI-ESWT restored microvascular density (microCT), renal oxygenation (BOLD-MRI), and stenotic kidney GFR • Expression of angiogenic markers VEGF, eNOS, and angiopoietin-1 increased, and fibrosis decreased after LI-ESWT • Beta1-integrin and FAK were upregulated after LI-ESWT indicating a potential role in mechanotransduction • No side effects to LI-ESWT (no haematuria, microscopic haemorrhage, or elevated proteinuria and NGAL levels)
Xue et al ¹²	<ul style="list-style-type: none"> • LI-ESWT improved NGAL, KIM-1, creatinine, and cystatin C serum levels as well as renal histology injury scores • Markers of oxidative stress (iNOS and malondialdehyde) were decreased by LI-ESWT • The effects of LI-ESWT seemed to weaken after one week • LI-ESWT did not cause any side effects in regard to any of the measured parameters

(Continued)

Table 2 (Continued).

Study	Main Findings
Zhang et al ¹³	<ul style="list-style-type: none"> LI-ESWT reduced mean arterial blood pressure Renal medullary and cortical fibrosis were reduced after LI-ESWT as demonstrated by trichrome staining
Chen et al ¹⁴	<ul style="list-style-type: none"> Renal cortical oxygenation was restored by LI-ESWT as demonstrated by BOLD-MRI Stenotic kidney GFR, serum creatinine, renal vein renin activity, and VEGF expression were not significantly different between PTRAs compared to PTRAs+LI-ESWT Fewer inflammatory macrophages and increased number of reparative macrophages in kidney after LI-ESWT LI-ESWT increased the density of peritubular capillaries as well as attenuated medullary fibrosis and tubular injury
Hsiao et al ¹⁵	<ul style="list-style-type: none"> LI-ESWT reduced albuminuria and restored renal VEGF expression to normal levels. Renal inflammation was reduced as shown by reduced IL-6 and IL-1β and increased anti-inflammatory M2 macrophages and IL-10. LI-ESWT reduced oxidative stress (\downarrow8-OHdG, \uparrowHO-1), renal fibrosis (\downarrowTGF-β1, \downarrowcollagen-I, \downarrowfibronectin), and glomerular hypertrophy. Podocyte regeneration and cellular proliferation were improved by LI-ESWT.
Sung et al ¹⁶	<ul style="list-style-type: none"> LI-ESWT reduced renal fibrosis and injury as well as markers of oxidative stress (NOX1, NOX2, oxidized protein), apoptosis (mitochondrial Bax, c-caspase3, c-PARP), and inflammation (TNF-α, NF-κB, MMP-2) LI-ESWT increased endothelial cells and expression of angiogenic factors (eNOS, CD31, and VEGF) Renal blood flow, serum BUN and creatinine levels, and urine protein excretion were improved by LI-ESWT The positive effects of LI-ESWT were enhanced in combination with EPCs + DPP4-inhibitor
Yoshida et al ¹⁷	<ul style="list-style-type: none"> Plasma creatinine was reduced in early phase after LI-ESWT LI-ESWT upregulated cortical VEGF mRNA in the non-occluded kidney in early phase and promoted lymphangiogenesis in the occluded kidney in late phase No significant effect of LI-ESWT on renal interstitial fibrosis, macrophage infiltration, or eNOS mRNA expression
Zhao et al ¹⁸	<ul style="list-style-type: none"> LI-ESWT restored GFR, perfusion, urinary protein excretion, arterial blood pressure, and endothelial function (vascular flow response to acetylcholine) The number of circulating EPCs was increased by LI-ESWT. There was a negative gradient of EPCs from renal arterial blood to renal vein blood suggesting a retention of EPCs in the kidney after LI-ESWT Circulating levels of SDF-1 and angiopoietin-1 were increased in pigs treated with LI-ESWT LI-ESWT improved the number of peritubular capillaries, increased the expression of VEGF and eNOS, and alleviated renal fibrosis (trichrome staining)
Chen et al ¹⁹	<ul style="list-style-type: none"> LI-ESWT monotherapy improved microvascular density (microCT), renal oxygenation (BOLD-MRI), and stenotic kidney GFR LI-ESWT monotherapy reduced renal fibrosis (trichrome staining) and inflammation (\downarrowTNF-α, \downarrowMCP-1, \uparrowIL-10) LI-ESWT in combination with MSC therapy improved the expression of eNOS and endothelial function (vascular flow response to acetylcholine) MSC therapy enhanced the positive effects of LI-ESWT on oxidative stress and peritubular capillary density Arterial blood pressure was not improved by LI-ESWT with or without MSC therapy. However, renal vein renin activity was significantly decreased by LI-ESWT
Liu et al ²⁰	<ul style="list-style-type: none"> LI-ESWT monotherapy attenuated changes in BUN, serum creatinine, and cystatin C after ischemic reperfusion injury LI-ESWT reduced renal tubular injury and apoptosis LI-ESWT increased cell proliferation, microvessel density, and amount of EPCs LI-ESWT increased the recruitment of circulating EPCs via upregulation of SDF-1 and CXCR7 receptor in the kidney
Skov-Jeppesen et al ^{21,22}	<ul style="list-style-type: none"> LI-ESWT caused short-lasting macroscopic haematuria in 6 out of 28 patients Most patients experienced flank tenderness up to 2 days after LI-ESWT GFR and 24-hour urinary excretion of albuminuria were stable up to 6 months after LI-ESWT No haematoma detected on ultrasound and ambulatory blood pressure remained stable No negative impact of LI-ESWT on kidney injury markers (KIM-1, calbindin, clusterin, osteoactivin, TFF3) Nitric oxide metabolites tended to increase in urine after LI-ESWT. VEGF decreased transiently one month after LI-ESWT (not strong evidence, $p=0.056$).

Abbreviations: VEGFR2, vascular endothelial growth factor receptor 2; HIF-1 α , hypoxia-inducible factor 1- α ; BOLD-MRI, blood-oxygen-level-dependent magnetic resonance imaging; FAK, focal adhesion kinase; NGAL, neutrophil gelatinase-associated lipocalin; KIM-1, kidney injury molecule-1; iNOS, inducible nitric oxide synthase; PTRAs, percutaneous transluminal renal angioplasty; 8-OHdG, 8-hydroxy-2'-deoxyguanosine; HO-1, heme oxygenase-1; TGF- β 1, transforming growth factor- β 1; NOX, NADPH oxidase; c-PARP, cleaved poly ADP ribose polymerase; TNF- α , tumor necrosis factor- α ; NF- κ B, nuclear factor kappa-light-chain-enhancer of activated B cells; MMP-2, matrix metalloproteinase-2; EPC, endothelial progenitor cells; DPP4, dipeptidyl-peptidase 4; SDF-1, stromal cell-derived factor-1; MCP-1, monocyte chemoattractant protein-1; MSC, mesenchymal stem cells.

Discussion

Shockwave therapy was invented originally for renal lithotripsy almost 40 years ago.²⁷ The application of LI-ESWT as a treatment for kidney parenchymal diseases is a novel therapeutic approach, and data in this field are limited. The earliest study we identified was published in 2016, and, since then, nine additional preclinical animal studies and one human study have been published with renal outcome as primary effect parameter.

Taken together, data from animal studies vary from neutral to positive findings that range from improved GFR, attenuated proteinuria and inflammation, improved renal blood flow, and lower blood pressure. Variation between the

Table 3 Selected Effects of LI-ESWT

Study	Molecular Effects			Cellular and Histological Effects			Renal Functional Effects		
	VEGF	NO/eNOS	TGF-Beta	Vascularization	Fibrosis	Inflammation	GFR	Perfusion	Blood Pressure
Caron et al ¹⁰	No effect	No effect	NA	NA	No effect	NA	NA	NA	No effect
Zhang et al ¹¹	Positive	Positive	Positive	Positive	Positive	NA	Positive	Positive	Positive
Xue et al ¹²	NA	Negative ^a	NA	NA	NA	NA	Positive ^b	NA	NA
Zhang et al ¹³	NA	NA	NA	NA	Positive	NA	NA	NA	Positive
Chen et al ¹⁴	No effect	NA	NA	Positive	Positive	Positive	Positive	Positive	NA
Hsiao et al ¹⁵	Positive	NA	Positive	NA	NA	Positive	NA	NA	NA
Sung et al ¹⁶	Positive	Positive	Positive	Positive	Positive	NA	Positive ^b	Positive	NA
Yoshida et al ¹⁷	Positive	No effect	NA	Positive	No effect	No effect	Positive ^b	NA	NA
Zhao et al ¹⁸	Positive	Positive	NA	Positive	Positive	NA	Positive	Positive	Positive
Chen et al ¹⁹	NA	Positive ^c	NA	Positive	Positive	Positive	Positive	Positive	No effect
Liu et al ²⁰	NA	NA	NA	Positive	NA	NA	Positive ^b	NA	NA
Skov-Jeppesen et al ^{21,22}	No effect ^d	No effect ^d	NA	NA	NA	NA	No effect ^d	NA	No effect ^d

Notes: ^aLower iNOS after LI-ESWT. ^bGFR not measured directly. Improved GFR was indicated by lower cystatin C, BUN, or creatinine after LI-ESWT. ^cLI-ESWT in combination with MSC therapy caused an upregulation of renal eNOS. ^dThe clinical study by Skov-Jeppesen et al was conducted as a single arm-interventional study with no comparative control group. Accordingly, the statement of “No effect” should be interpreted as no significant changes from baseline to follow-up.

results can be ascribed to different models of renal disease, different species, and different therapeutic protocols. In light of the non-invasive intervention, there is a need for functional and tissue data from human intervention trials.

Previous studies, focusing on other organs than kidneys, showed that the effect of LI-ESWT was mediated through different receptors and proteins associated with cell surfaces, including specific mechanosensory complexes, toll-like receptors, and ATP receptors that were activated by ATP released from cytoplasm in response to LI-ESWT.^{28–30} This way, LI-ESWT acts as a physical stimulus that potentially influences several types of cell surface receptors. The beneficial downstream signalling effects of LI-ESWT involve local angiogenesis as well as anti-inflammatory processes summarizing into reduced fibrosis. At the level of signalling pathways, LI-ESWT upregulates VEGF and NO which act as trophic factors for endothelium and stimulation of angiogenesis. VEGF and VEGF receptor activation were previously shown to be higher after LI-ESWT in heart, skeletal muscle, skin, and penile tissue.^{31–35} The activation of angiogenesis by LI-ESWT leads to improved tissue perfusion and oxygenation as shown clinically in ischemic myocardium and diabetic foot ulcers.^{36–38} Also, treatment with ESWL has previously been associated with increased levels of plasma nitrite and cyclic 3', 5'-guanosine monophosphate (cGMP) suggesting that shockwaves stimulate the NO-cGMP signaling pathway.^{39–41}

Histologically, LI-ESWT may promote tissue remodelling through activation of M2 reparative macrophages and inhibition of M1 inflammatory macrophages.⁴² In severe burn wounds and myocardial infarction, treatment with LI-ESWT suppressed pro-inflammatory cytokines and neutrophil and macrophage infiltration.^{43,44} LI-ESWT ameliorated TGF-beta expression and tissue collagen and fibrocyte content as demonstrated in ischemic heart diseases.^{44–46} Interestingly, a few studies indicated a synergistic effect between administration of endothelial progenitor cells and LI-ESWT to induce angiogenesis and improved tissue viability.^{47,48} It is likely that LI-ESWT upregulates the local production of SDF-1 which may attract circulating endothelial progenitor cells.^{47,49} This way, LI-ESWT treatment could provide a method to enhance cell-based therapies.

Only a few studies have tested the dose–response relationship of LI-ESWT. The treatment can be administered with lower or higher energy within the spectrum from 0.01 to 0.35 mJ/mm². In the hind limb of rats, tissue oxygen tension was significantly higher after application with energy at 0.30 mJ/mm² compared to energy at 0.10 mJ/mm².⁵⁰ On the

other hand, an inappropriate high number of shockwaves might induce tissue necrosis.⁵¹ Furthermore, repetitive sessions of LI-ESWT have been found to negatively affect wound healing.⁵² With regard to the optimal timing of treatment, application of LI-ESWT to acutely injured skin showed there was no difference whether treatment was applied before or after ischemic injury.⁵³ Hypothetically, another useful application of LI-ESWT could be a preconditioning treatment in relation to surgical procedures that induce renal ischemia, ie, partial nephrectomy or renal transplantation. Furthermore, LI-ESWT can be applied as either focused or radial therapy. Radial shockwaves differ from focused shockwaves in that they propagate in the body as spherical waves and do not focus the energy in a small, targeted area.⁵ In renal diseases, LI-ESWT was carried out as focused therapy in all of the studies and the potential of radial LI-ESWT is unknown.

In the present review of data from studies with primary renal outcome, LI-ESWT elicited beneficial effects as found in other organs, but some of the findings were not consistent between the studies with different renal disease models. In particular, Caron et al¹⁰ demonstrated no positive effects of LI-ESWT treatment. Of note, their study was based on rats with hypertensive renal disease induced by administration of L-NAME. The majority of the animal studies were based on renal artery stenosis/clamping and thus studied ischemia recovery and reperfusion injury. However, Hsiao et al¹⁵ based their renal disease model on streptozotocin injection to induce type 1 diabetic nephropathy and found positive effects of renal LI-ESWT. In relation to the method of LI-ESWT administration, we identified no simple differences that could explain the discrepancy between the outcomes. LI-ESWT was administered in the same way through all of the porcine studies, and the reported outcomes in these studies were overall positive and constitute the only data in large animals. However, only one type of renal disease model (ischemic renal disease) was used in the porcine studies. It remains unclear whether the protocol for LI-ESWT implemented in the porcine studies is also efficient in other types of renal diseases. In general, LI-ESWT was applied with energy densities in the lower end of the spectrum in the animal studies (0.09–0.13 mJ/mm²). Conversely, patients included in the clinical study were treated with relatively high energy levels at 0.265 mJ/mm². There were no clear associations between the frequency or number of sessions of LI-ESWT and the outcomes. The most frequently used protocol for LI-ESWT was twice per week for 3 weeks for a total of six sessions but ranged from one session up to 12 sessions in total. A consistent finding across the preclinical studies was that there was no evidence of injury or damage to the kidneys.

The single human study was conducted as phase 1 study in order to first establish the clinical safety of LI-ESWT in renal parenchymal disease.^{21,22} In this study, transient macroscopic haematuria was observed in a minor part of the patients. Flank tenderness was more commonly reported after bilateral LI-ESWT. These side effects are well-known also from ESWL. The side effects did not require any intervention or treatment and were short-lasting after LI-ESWT. There were no reported signs of renal hematoma or negative functional outcomes (drop in GFR, hypertension, or albuminuria) related to LI-ESWT, and further clinical research is encouraged. In particular, future clinical studies should test the dose–response relationship of LI-ESWT considering the positive results demonstrated in animal studies at relatively low energy settings. Moreover, the optimal frequency of LI-ESWT and whether intervention can be repeated should be clarified.

Conclusions

LI-ESWT has shown several beneficial outcomes in ischemic cardiac disease, erectile dysfunction, and skin injury. Data on the effect in renal parenchymal diseases are scarce. In preclinical animal studies, LI-ESWT showed no adverse effects. In some cases, significant improvement was found in VEGF synthesis and renal vascularity with reduced renal fibrosis and improved renal function. There was a large heterogeneity between the studies with regard to the administration of LI-ESWT (intensity, frequency) and the type of renal disease. In a clinical setting, LI-ESWT has proven as a safe treatment in a small study population of patients with diabetic nephropathy. Future randomized controlled clinical trials are needed to determine the efficacy of LI-ESWT in renal diseases.

Abbreviations

LI-ESWT, low-intensity extracorporeal shockwave therapy; VEGF, vascular endothelial growth factor; NO, nitric oxide; eNOS, endothelial nitric oxide synthase; GFR, glomerular filtration rate; SDF-1, stromal cell-derived factor-1; BOLD MRI, blood oxygen-level-dependent magnetic resonance imaging.

Data Sharing Statement

All articles included in this systematic review are referenced in the manuscript.

Author Contributions

All authors made a significant contribution to the work reported, whether that is in the conception, study design, execution, acquisition of data, analysis and interpretation, or in all these areas. All authors contributed to data analysis, drafting or revising the article, have agreed on the journal to which the article will be submitted, gave final approval of the version to be published, and agree to be accountable for all aspects of the work.

Disclosure

The authors declare that they have no competing interests.

References

1. Burneikaite G, Shkolnik E, Celutkienė J, et al. Cardiac shock-wave therapy in the treatment of coronary artery disease: systematic review and meta-analysis. *Cardiovasc Ultrasound*. 2017;15(1):11. doi:10.1186/s12947-017-0102-y
2. Cayton T, Harwood A, Smith GE, Chetter I. A systematic review of extracorporeal shockwave therapy as a novel treatment for intermittent claudication. *Ann Vasc Surg*. 2016;35:226–233. doi:10.1016/j.avsg.2016.02.017
3. Huang Q, Yan P, Xiong H, et al. Extracorporeal shock wave therapy for treating foot ulcers in adults with type 1 and type 2 diabetes: a systematic review and meta-analysis of randomized controlled trials. *Can J Diabetes*. 2019;2019:1.
4. Sokolakis I, Hatzichristodoulou G. Clinical studies on low intensity extracorporeal shockwave therapy for erectile dysfunction: a systematic review and meta-analysis of randomised controlled trials. *Int J Impot Res*. 2019;31(3):177–194. doi:10.1038/s41443-019-0117-z
5. d'Agostino MC, Craig K, Tibalt E, Respizzi S. Shock wave as biological therapeutic tool: from mechanical stimulation to recovery and healing, through mechanotransduction. *Int J Surg*. 2015;24(PtB):147–153. doi:10.1016/j.ijssu.2015.11.030
6. Hatanaka K, Ito K, Shindo T, et al. Molecular mechanisms of the angiogenic effects of low-energy shock wave therapy: roles of mechanotransduction. *Am J Physiol Cell Physiol*. 2016;311(3):C378–85. doi:10.1152/ajpcell.00152.2016
7. Peng YZ, Zheng K, Yang P, et al. Shock wave treatment enhances endothelial proliferation via autocrine vascular endothelial growth factor. *Genet Mol Res*. 2015;14(4):19203–19210. doi:10.4238/2015.December.29.30
8. Yan X, Zeng B, Chai Y, Luo C, Li X. Improvement of blood flow, expression of nitric oxide, and vascular endothelial growth factor by low-energy shockwave therapy in random-pattern skin flap model. *Ann Plast Surg*. 2008;61(6):646–653. doi:10.1097/SAP.0b013e318172ba1f
9. DIGEST. Guidelines for extracorporeal shock wave therapy. The International Society for Medical Shockwave Treatment; 2019. Available from: https://www.shockwavetherapy.org/fileadmin/user_upload/ISMST_Guidelines.pdf. Accessed February 3, 2023.
10. Caron J, Michel PA, Dussault JC, Chatziantoniou C, Ronco P, Boffa JJ. Extracorporeal shock wave therapy does not improve hypertensive nephropathy. *Physiol Rep*. 2016;4:11. doi:10.14814/phy2.12699
11. Zhang X, Krier JD, Amador Carrascal C, et al. Low-energy shockwave therapy improves ischemic kidney microcirculation. *J Am Soc Nephrol*. 2016;27(12):3715–3724. doi:10.1681/ASN.2015060704
12. Xue Y, Xu Z, Chen H, Gan W, Chong T. Low-energy shock wave preconditioning reduces renal ischemic reperfusion injury caused by renal artery occlusion. *Acta Cir Bras*. 2017;32(7):550–558. doi:10.1590/s0102-865020170070000006
13. Zhang X, Zhu X, Ferguson CM, et al. Magnetic resonance elastography can monitor changes in medullary stiffness in response to treatment in the swine ischemic kidney. *MAGMA*. 2018;31(3):375–382. doi:10.1007/s10334-017-0671-7
14. Chen XJ, Zhang X, Jiang K, et al. Improved renal outcomes after revascularization of the stenotic renal artery in pigs by prior treatment with low-energy extracorporeal shockwave therapy. *J Hypertens*. 2019;37:2074–2082. doi:10.1097/HJH.0000000000002158
15. Hsiao CC, Huang WH, Cheng KH, Lee CT. Low-energy extracorporeal shock wave therapy ameliorates kidney function in diabetic nephropathy. *Oxid Med Cell Longev*. 2019;2019:8259645. doi:10.1155/2019/8259645
16. Sung PH, Chen KH, Li YC, Chiang JY, Lee MS, Yip HK. Sitagliptin and shock wave-supported peripheral blood derived endothelial progenitor cell therapy effectively preserves residual renal function in chronic kidney disease in rat-role of dipeptidyl peptidase 4 inhibition. *Biomed Pharmacother*. 2019;111:1088–1102. doi:10.1016/j.biopha.2019.01.025
17. Yoshida M, Nakamichi T, Mori T, Ito K, Shimokawa H, Ito S. Low-energy extracorporeal shock wave ameliorates ischemic acute kidney injury in rats. *Clin Exp Nephrol*. 2019;23(5):597–605. doi:10.1007/s10157-019-01689-7
18. Zhao Y, Santelli A, Zhu XY, et al. Low-energy shockwave treatment promotes endothelial progenitor cell homing to the stenotic pig kidney. *Cell Transplant*. 2020;29:963689720917342. doi:10.1177/0963689720917342
19. Chen XJ, Zhang X, Jiang K, et al. Adjunctive mesenchymal stem/stromal cells augment microvascular function in poststenotic kidneys treated with low-energy shockwave therapy. *J Cell Physiol*. 2020;235:9806–9818. doi:10.1002/jcp.29794

20. Liu J, Dou Q, Zhou C, et al. Low-energy shock wave pretreatment recruit circulating endothelial progenitor cells to attenuate renal ischaemia reperfusion injury. *J Cell Mol Med*. 2020;24(18):10589–10603. doi:10.1111/jcmm.15678
21. Skov-Jepesen SM, Yderstraede KB, Bistrup C, et al. Low-intensity shockwave therapy in the treatment of diabetic nephropathy: a prospective Phase 1 study. *Nephrol Dial Transplant*. 2018;2018:1.
22. Skov-Jepesen SM, Yderstraede KB, Jensen BL, Bistrup C, Hanna M, Lund L. Low-Intensity Shockwave Therapy (LI-ESWT) in diabetic kidney disease: results from an open-label interventional clinical trial. *Int J Nephrol Renovasc Dis*. 2021;14:255–266. doi:10.2147/IJNRD.S315143
23. Michel PA, Bonin P, Bige N, et al. Effects of shock wave therapy in chronic kidney diseases. *Nephron Physiol*. 2011;1:p12.
24. Hanna M, Pedersen D, Lund M, Marcussen N, Lund L. Low energy ESWT, a novel treatment for diabetic nephropathy (animal study). *J Endourol*. 2012;1:A6.
25. Lundrup RN, Skov-Jepesen SM, Bistrup C, Jensen B, Yderstraede K, Lund L. Safety and effect of low-energy extracorporeal shockwave therapy (ESWT) on the renal allograft in transplant recipients-preliminary results. *Scand J Urol*. 2019;53(Supplement 221):4.
26. Aleksandre B, Andro D, Milad H, et al. Low intensity shock waves in the treatment of diabetic nephropathy: prospective, phase 1 study, Georgian arm. *Eur Urol Suppl*. 2019;18(12):e3635–e6. doi:10.1016/S1569-9056(19)35038-9
27. Chaussy C, Brendel W, Schmiedt E. Extracorporeally induced destruction of kidney stones by shock waves. *Lancet*. 1980;2(8207):1265–1268. doi:10.1016/S0140-6736(80)92335-1
28. Ha CH, Kim S, Chung J, An SH, Kwon K. Extracorporeal shock wave stimulates expression of the angiogenic genes via mechanosensory complex in endothelial cells: mimetic effect of fluid shear stress in endothelial cells. *Int J Cardiol*. 2013;168(4):4168–4177. doi:10.1016/j.ijcard.2013.07.112
29. Holfeld J, Tepekoylu C, Reissig C, et al. Toll-like receptor 3 signalling mediates angiogenic response upon shock wave treatment of ischaemic muscle. *Cardiovasc Res*. 2016;109(2):331–343. doi:10.1093/cvr/cvv272
30. Weihs AM, Fuchs C, Teuschl AH, et al. Shock wave treatment enhances cell proliferation and improves wound healing by ATP release-coupled extracellular signal-regulated kinase (ERK) activation. *J Biol Chem*. 2014;289(39):27090–27104. doi:10.1074/jbc.M114.580936
31. Holfeld J, Zimpfer D, Albrecht-Schgoer K, et al. Epicardial shock-wave therapy improves ventricular function in a porcine model of ischaemic heart disease. *J Tissue Eng Regen Med*. 2014;2014:1.
32. Cai HY, Li L, Guo T, et al. Cardiac shockwave therapy improves myocardial function in patients with refractory coronary artery disease by promoting VEGF and IL-8 secretion to mediate the proliferation of endothelial progenitor cells. *Exp Ther Med*. 2015;10(6):2410–2416. doi:10.3892/etm.2015.2820
33. Jeong HC, Jeon SH, Qun ZG, et al. Effects of next-generation low-energy extracorporeal shockwave therapy on erectile dysfunction in an animal model of diabetes. *World J Mens Health*. 2017;35(3):186–195. doi:10.5534/wjmh.17024
34. Wang CJ, Ko JY, Kuo YR, Yang YJ. Molecular changes in diabetic foot ulcers. *Diabetes Res Clin Pract*. 2011;94(1):105–110. doi:10.1016/j.diabres.2011.06.016
35. Holfeld J, Tepekoylu C, Blunder S, et al. Low energy shock wave therapy induces angiogenesis in acute hind-limb ischemia via VEGF receptor 2 phosphorylation. *PLoS One*. 2014;9(8):e103982. doi:10.1371/journal.pone.0103982
36. Kaller M, Faber L, Bogunovic N, Horstkotte D, Burchert W, Lindner O. Cardiac shock wave therapy and myocardial perfusion in severe coronary artery disease. *Clin Res Cardiol*. 2015;104(10):843–849. doi:10.1007/s00392-015-0853-0
37. Wang CJ, Wu RW, Yang YJ. Treatment of diabetic foot ulcers: a comparative study of extracorporeal shockwave therapy and hyperbaric oxygen therapy. *Diabetes Res Clin Pract*. 2011;92(2):187–193. doi:10.1016/j.diabres.2011.01.019
38. Jepesen SM, Yderstraede KB, Rasmussen BS, Hanna M, Lund L. Extracorporeal shockwave therapy in the treatment of chronic diabetic foot ulcers: a prospective randomised trial. *J Wound Care*. 2016;25(11):641–649. doi:10.12968/jowc.2016.25.11.641
39. Park JK, Cui Y, Kim MK, et al. Effects of extracorporeal shock wave lithotripsy on plasma levels of nitric oxide and cyclic nucleotides in human subjects. *J Urol*. 2002;168(1):38–42. doi:10.1016/S0022-5347(05)64827-6
40. Sarica K, Balat A, Erbagci A, Cekmen M, Yurekli M, Yagci F. Effects of shock wave lithotripsy on plasma and urinary levels of nitrite and adrenomedullin. *Urol Res*. 2003;31(5):347–351. doi:10.1007/s00240-003-0351-0
41. Aksoy H, Aksoy Y, Turhan H, Keleş S, Ziyap T, Özbey I. The effect of shock wave lithotripsy on nitric oxide and malondialdehyde levels in plasma and urine samples. *Cell Biochem Funct*. 2007;25(5):533–536. doi:10.1002/cbf.1349
42. Sukubo NG, Tibalt E, Respizzi S, Locati M, d'Agostino MC. Effect of shock waves on macrophages: a possible role in tissue regeneration and remodeling. *Int J Surg*. 2015;24:124–130. doi:10.1016/j.ijssu.2015.07.719
43. Davis TA, Stojadinovic A, Anam K, et al. Extracorporeal shock wave therapy suppresses the early proinflammatory immune response to a severe cutaneous burn injury. *Int Wound J*. 2009;6(1):11–21. doi:10.1111/j.1742-481X.2008.00540.x
44. Abe Y, Ito K, Hao K, et al. Extracorporeal low-energy shock-wave therapy exerts anti-inflammatory effects in a rat model of acute myocardial infarction. *Circ J*. 2014;2014:1.
45. Fu M, Sun CK, Lin YC, et al. Extracorporeal shock wave therapy reverses ischemia-related left ventricular dysfunction and remodeling: molecular-cellular and functional assessment. *PLoS One*. 2011;6(9):e24342. doi:10.1371/journal.pone.0024342
46. Lei PP, Tao SM, Shuai Q, et al. Extracorporeal cardiac shock wave therapy ameliorates myocardial fibrosis by decreasing the amount of fibrocytes after acute myocardial infarction in pigs. *Coron Artery Dis*. 2013;24(6):509–515. doi:10.1097/MCA.0b013e3283640ec7
47. Aicher A, Heeschen C, Sasaki K, Urbich C, Zeiher AM, Dimmeler S. Low-energy shock wave for enhancing recruitment of endothelial progenitor cells: a new modality to increase efficacy of cell therapy in chronic hind limb ischemia. *Circulation*. 2006;114(25):2823–2830. doi:10.1161/CIRCULATIONAHA.106.628623
48. Assmus B, Walter DH, Seeger FH, et al. Effect of shock wave-facilitated intracoronary cell therapy on LVEF in patients with chronic heart failure: the CELLWAVE randomized clinical trial. *JAMA*. 2013;309(15):1622–1631. doi:10.1001/jama.2013.3527
49. Gollmann-Tepekoylu C, Lobenwein D, Theurl M, et al. Shock wave therapy improves cardiac function in a model of chronic ischemic heart failure: evidence for a mechanism involving VEGF signaling and the extracellular matrix. *J Am Heart Assoc*. 2018;7(20):e010025. doi:10.1161/JAHA.118.010025
50. Kraemer R, Sorg H, Forstmeier V, et al. Immediate dose-response effect of high-energy versus low-energy extracorporeal shock wave therapy on cutaneous microcirculation. *Ultrasound Med Biol*. 2016;42(12):2975–2982. doi:10.1016/j.ultrasmedbio.2016.08.010
51. Kamelger F, Oehlbauer M, Piza-Katzer H, Meirer R. Extracorporeal shock wave treatment in ischemic tissues: what is the appropriate number of shock wave impulses? *J Reconstr Microsurg*. 2010;26(2):117–121. doi:10.1055/s-0029-1243296

52. Zins SR, Amare MF, Tadaki DK, Elster EA, Davis TA. Comparative analysis of angiogenic gene expression in normal and impaired wound healing in diabetic mice: effects of extracorporeal shock wave therapy. *Angiogenesis*. 2010;13(4):293–304. doi:10.1007/s10456-010-9186-9
53. Mittermayr R, Hartinger J, Antonic V, et al. Extracorporeal shock wave therapy (ESWT) minimizes ischemic tissue necrosis irrespective of application time and promotes tissue revascularization by stimulating angiogenesis. *Ann Surg*. 2011;253(5):1024–1032. doi:10.1097/SLA.0b013e3182121d6e

International Journal of Nephrology and Renovascular Disease

Dovepress

Publish your work in this journal

The International Journal of Nephrology and Renovascular Disease is an international, peer-reviewed open-access journal focusing on the pathophysiology of the kidney and vascular supply. Epidemiology, screening, diagnosis, and treatment interventions are covered as well as basic science, biochemical and immunological studies. The manuscript management system is completely online and includes a very quick and fair peer-review system, which is all easy to use. Visit <http://www.dovepress.com/testimonials.php> to read real quotes from published authors.

Submit your manuscript here: <https://www.dovepress.com/international-journal-of-nephrology-and-renovascular-disease-journal>